



Faculty of Biological Science and Technology
Zoology and Botanical Department
Practical Histology

Accessory Organs of Digestive System

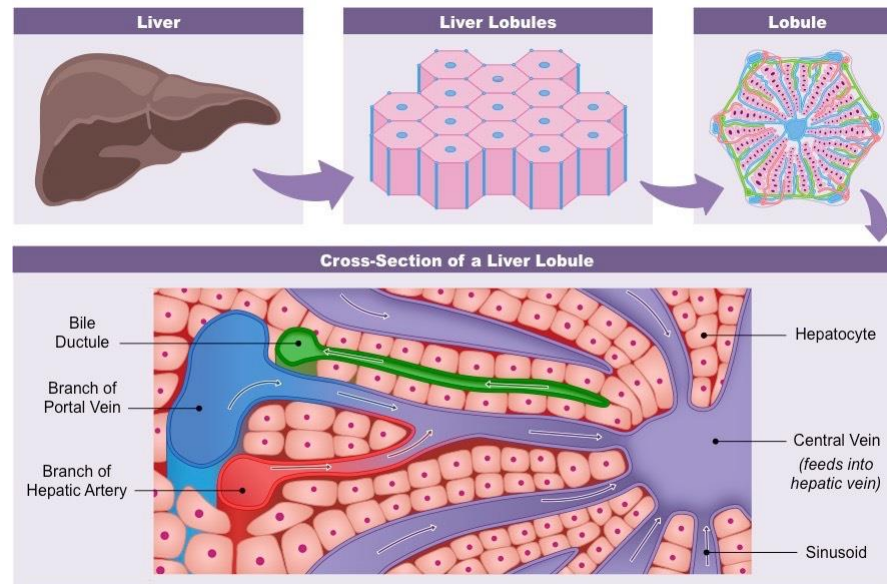
Part 2

By: Shirin Kashfi
Ph.D in Animal Development
Sh.kashfi@staf.ui.ac.ir



Liver

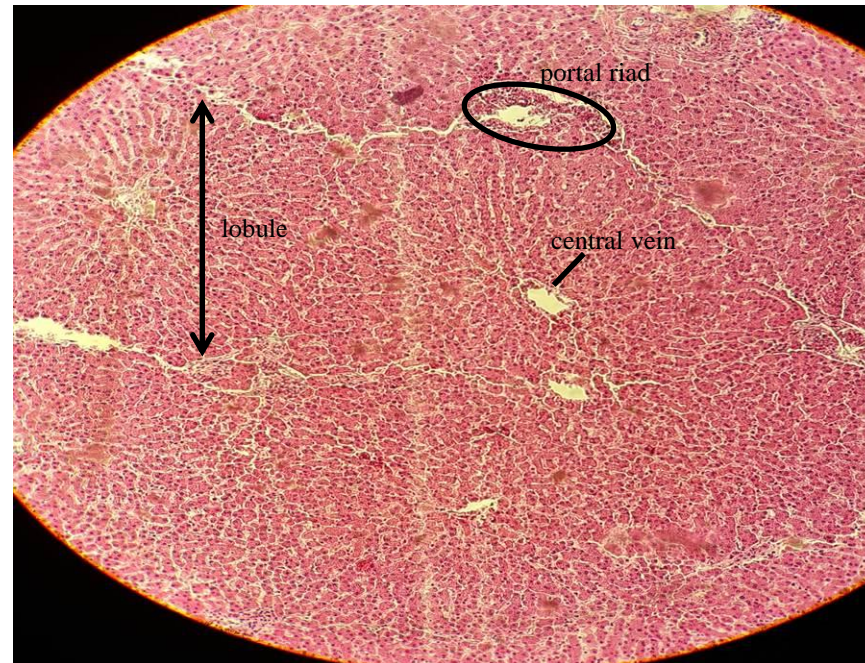
- ▶ Liver is the largest gland in the body
- ▶ This organ is enveloped by thin layer of connective tissue known as Glisson's capsule. Liver is also covered by peritoneum
- ▶ Liver parenchyma is composed of numerous small roughly hexagonal shape lobules. Within the lobules, hepatocytes arranged in cords. Specialized capillary known as sinusoids located between hepatocyte's cords
- ▶ Each hepatic lobule has a central vein at the center
- ▶ At the periphery of the lobules are three structure embedded in connective tissue collectively known as the portal triad



From: <https://ib.bioninja.com.au/options/option-d-human-physiology/d3-functions-of-the-liver/liver-structure.html>



Liver

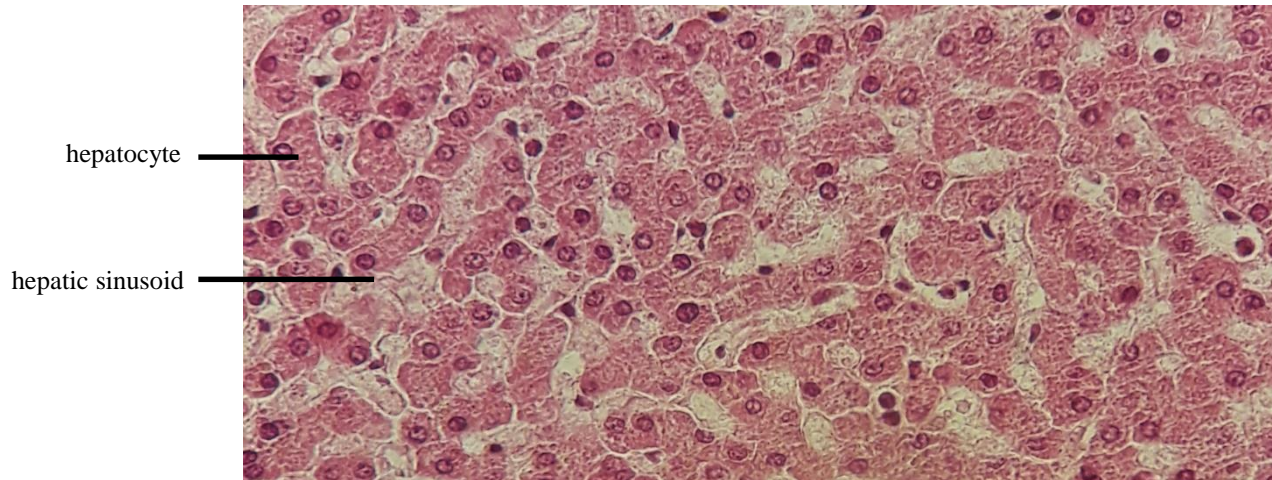


Liver parenchyma are made up of polygonal lobules. Portal triad is located at the periphery of lobules and central vein is seen in the center of each lobule. H&E, 4X. This picture is taken from histological slide in histology laboratory of Isfahan University



Liver: hepatocyte

- ▶ Hepatocyte have polygonal shape and large, spherical nucleus which located in the center of cell
- ▶ Hepatocytes generally have two nuclei
- ▶ Hepatocytes arranged in the form of cords (or plates), which radiate outwards from central vein
- ▶ The spaces between hepatic cords are occupied by sinusoids

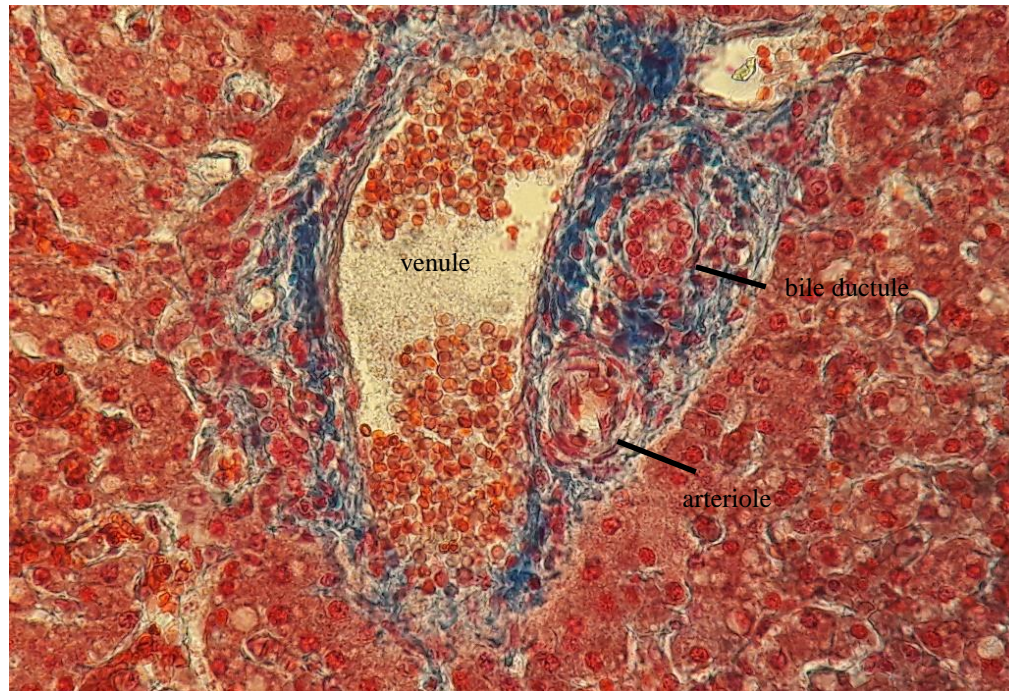


Cross section of liver. H&E, 100X. This picture is taken from histological slide in histology laboratory of Isfahan University



Liver: portal triad

- ▶ Each portal triad consists of a venule (branch of the portal vein), arteriole (branch of hepatic artery) and bile ductule
- ▶ Bile ductules are lined by simple cuboid epithelium

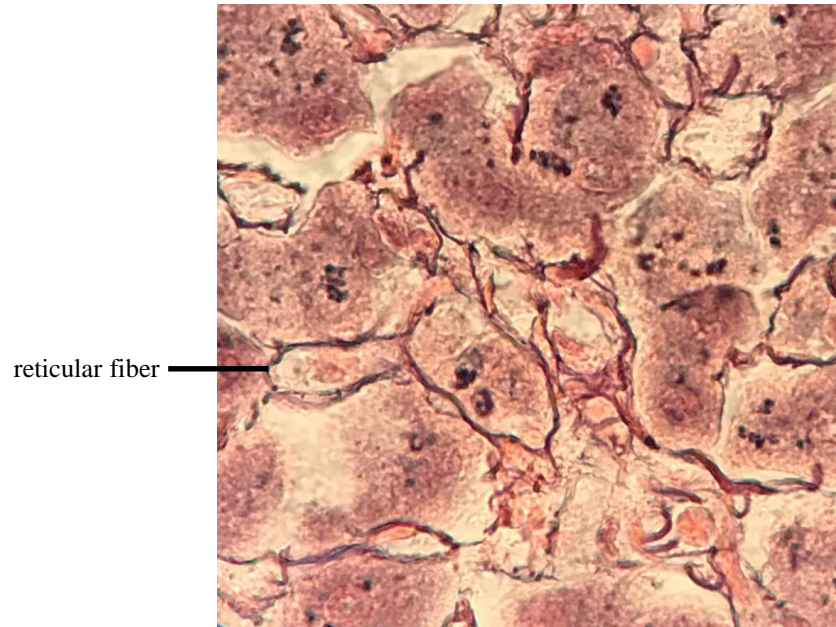


A portal triad and its component is shown in this cross section of liver. Note that venule has a larger lumen than arteriole. Besides, muscular layer is more prominent in arteriole. 40X. This picture is taken from histological slide in histology laboratory of Isfahan University



Liver: reticular fibers

- ▶ Reticular fibers (collagen type III) crosslink together to form a fine network known as reticulin
- ▶ This network of fibers supports soft tissue such as liver

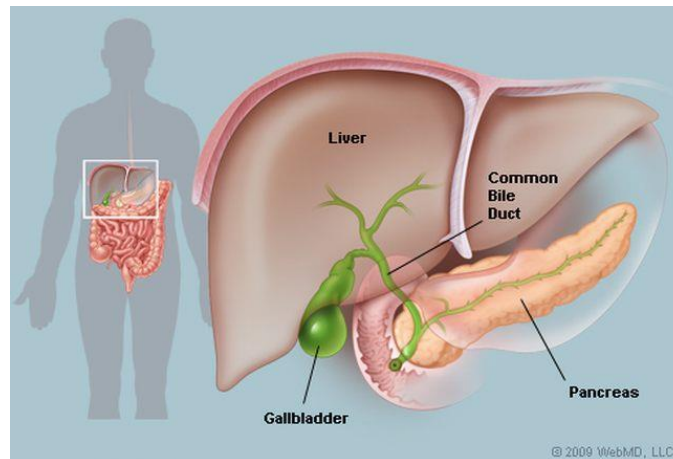


Cross section of liver. Thin reticular fibers are seen like black strands between hepatocytes. Reticulin staining, 100X. This picture is taken from histological slide in histology laboratory of Isfahan University



Gallbladder

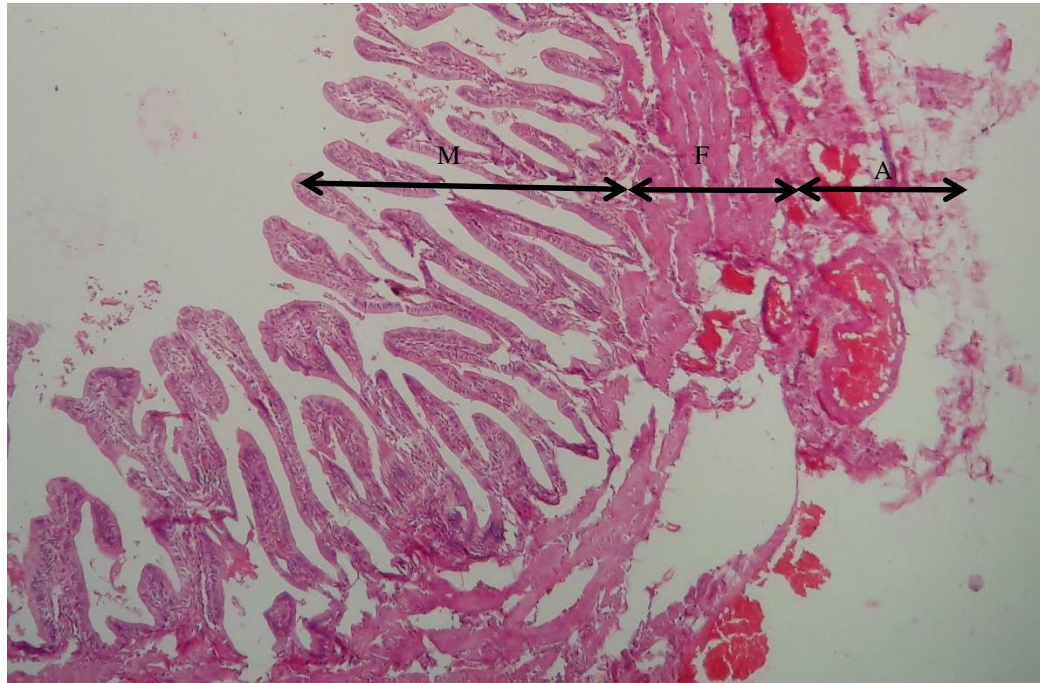
- ▶ Gallbladder is a hollow pear-shaped organ which is located beneath to liver. This organ acts as a storage place for bile from liver
- ▶ Histologically, the wall of gallbladder composed of three layers: Mucosa, muscular layer and serosa or adventitia
- ▶ The mucosa consists of simple columnar epithelium and underlying lamina propria. Gallbladder mucosa is highly folded which is seen better in empty organ
- ▶ Muscularis layer contains smooth muscle fibers oriented randomly
- ▶ Outer connective tissue is adventitia where the gallbladder attaches to the liver. Serosa covers the outer surface of gallbladder



From: <http://samir-rahmani-surgeon.co.uk/Biliary/GallBladder>



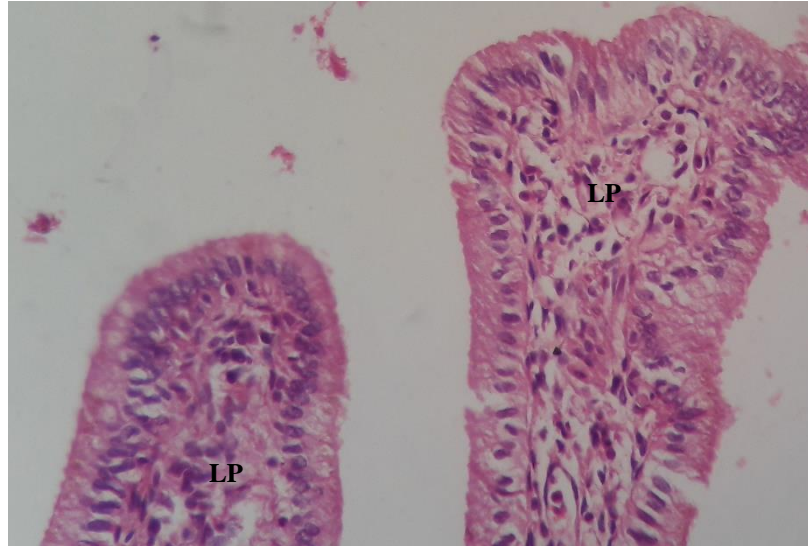
Gallbladder



Gallbladder. The mucosa of gallbladder (M) has rugae. There is no submucosa. Muscularis layer (F) composed of randomly oriented smooth muscle fibers. Adventitia (A) is seen. H&E, 4X. This picture is taken from histological slide in histology laboratory of Isfahan University



Gallbladder: mucosa



Gallbladder mucosa is made up of simple columnar epithelium with underlying lamina propria (LP). H&E, 40X. This picture is taken from histological slide in histology laboratory of Isfahan University