



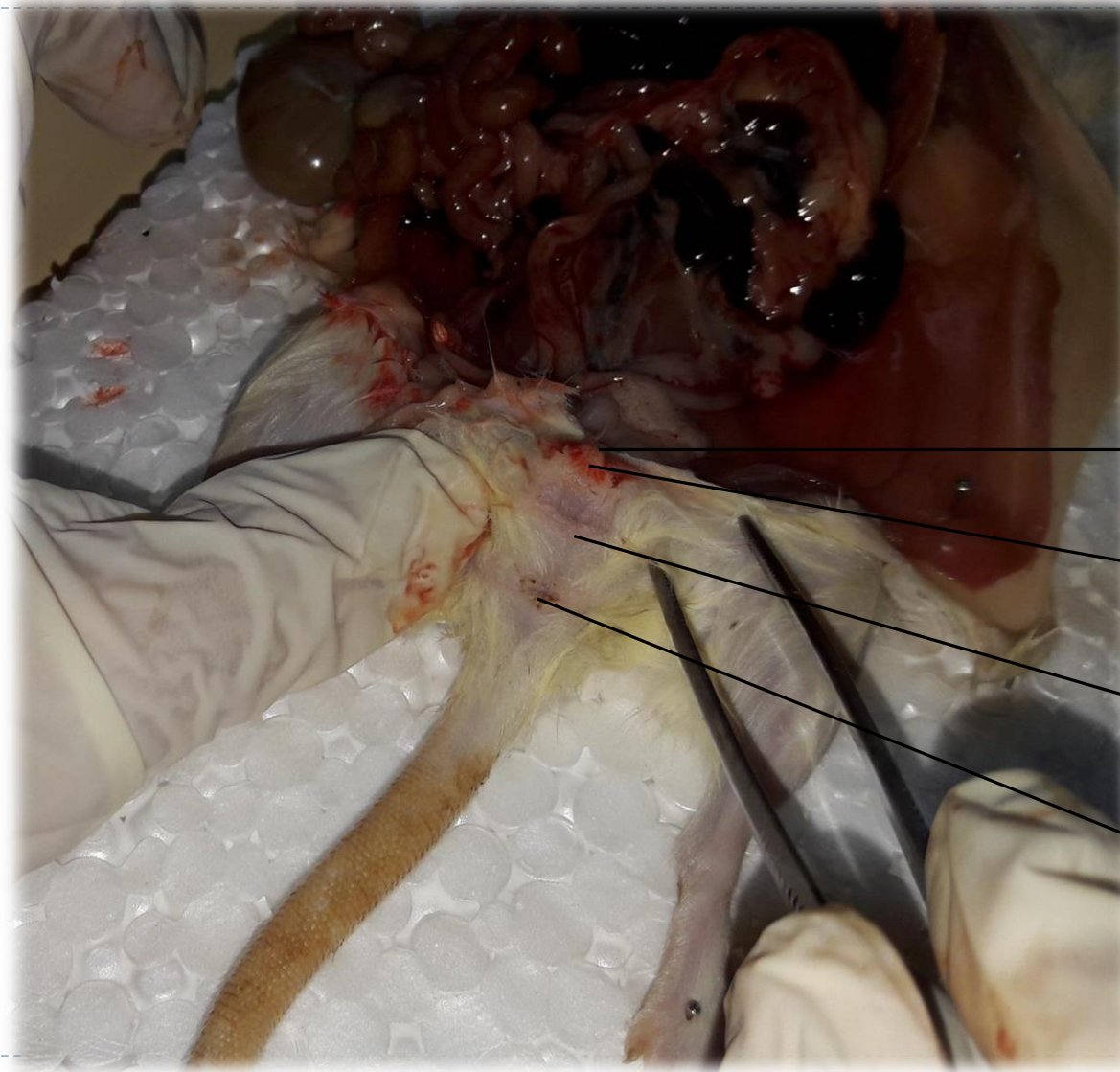Faculty of Biological Science and Technology
Zoology and Botanic Department
Practical Embryology

Rat Genital System Dissection

By: Shirin Kashfi
Ph.D in Animal Development
Sh.kashfi@staf.ui.ac.ir



How to recognize female from male rats?



- There is three pores in female genital area
- There are six pairs of mammary glands in two parallel row in female

urinary opening
منفذ ادراری

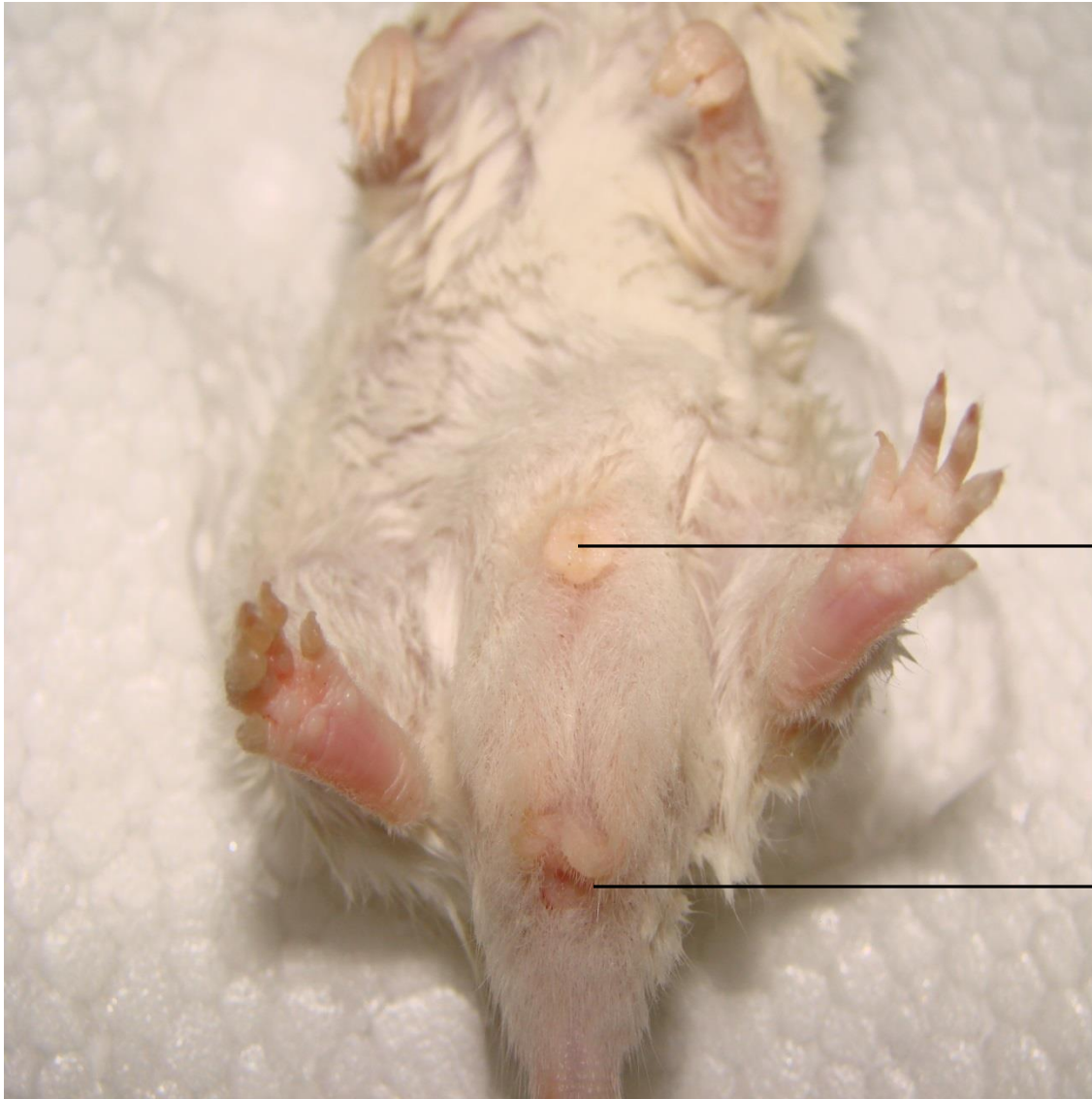
clitoris
کلیتوریس

Genital opening
منفذ تناسلی

anus
مخرج



How to recognize female from male rats?



- There is two pores in male genital area
- Urinary and sexual system use a single vent in male rats

urogenital opening
منفذ ادراری- تناسلی

anus
مخرج

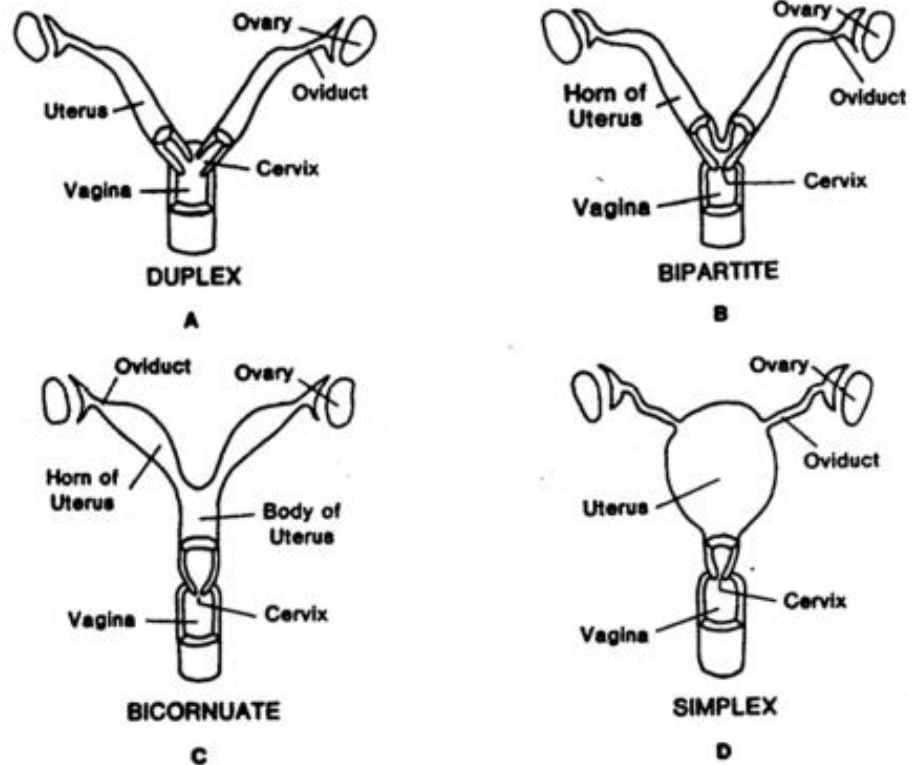


Genital system in female rat

- Genital system in female rats consist of
 - Paired ovaries
 - Paired oviducts
 - Uterus
- Rodents (e.g. Mouse, rats) and Logomorpha (e.g. rabbit) has the most primitive uterus known as **duplex uterus**
- Duplex uterus comprises two uterine horns with join together and open to vagina through two separate cervices



Types of uteri in eutherian mammals

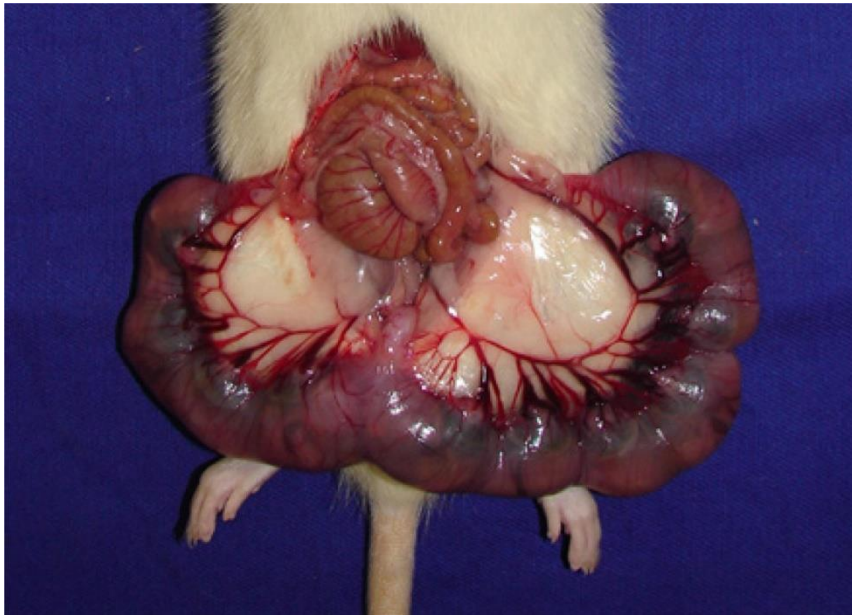


From: www.afrc.uamont.edu



Quiz time!

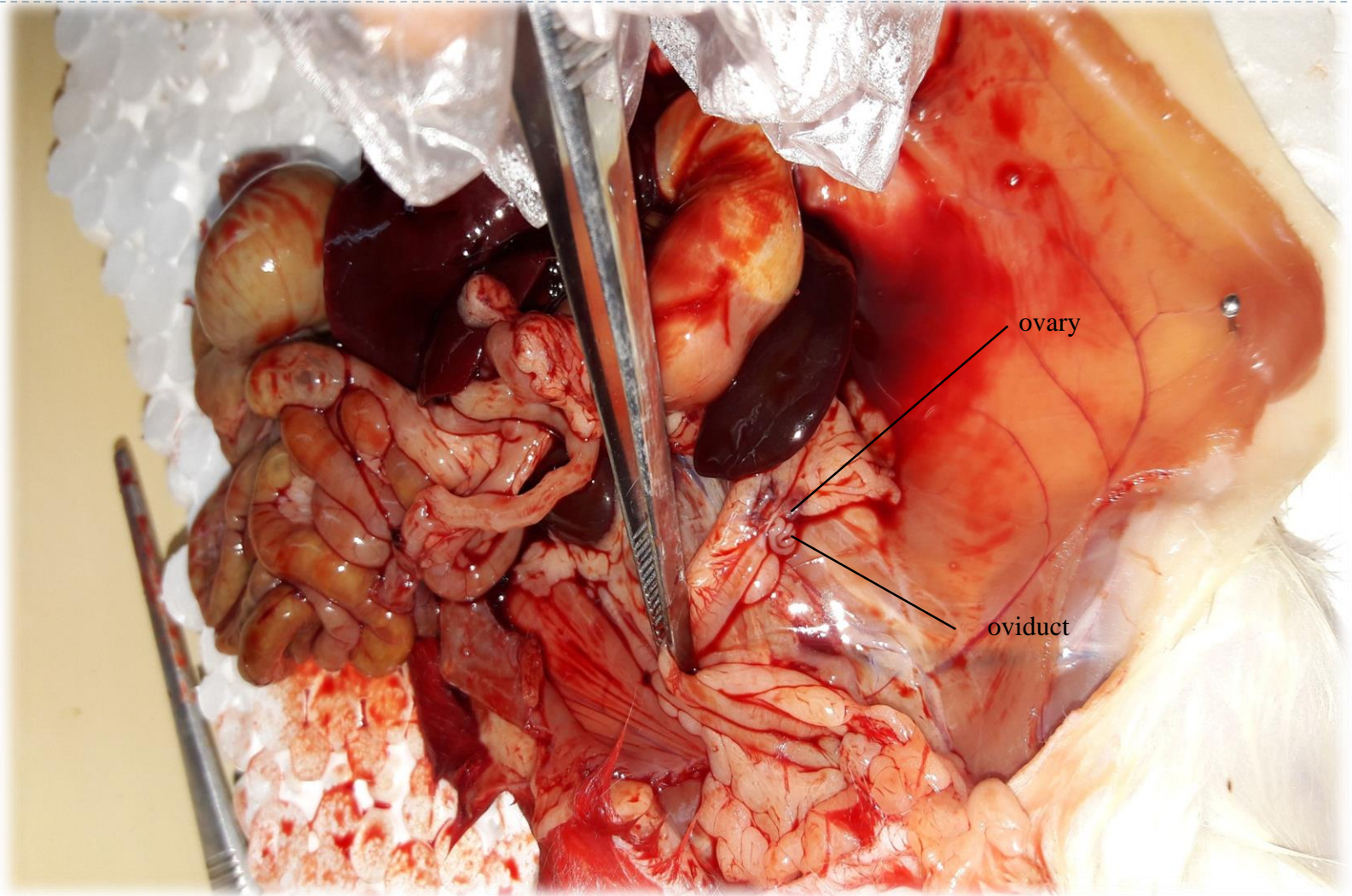
- What is the advantage of duplex uteri?



From: Figueiro-Filho *et al.*, 2014

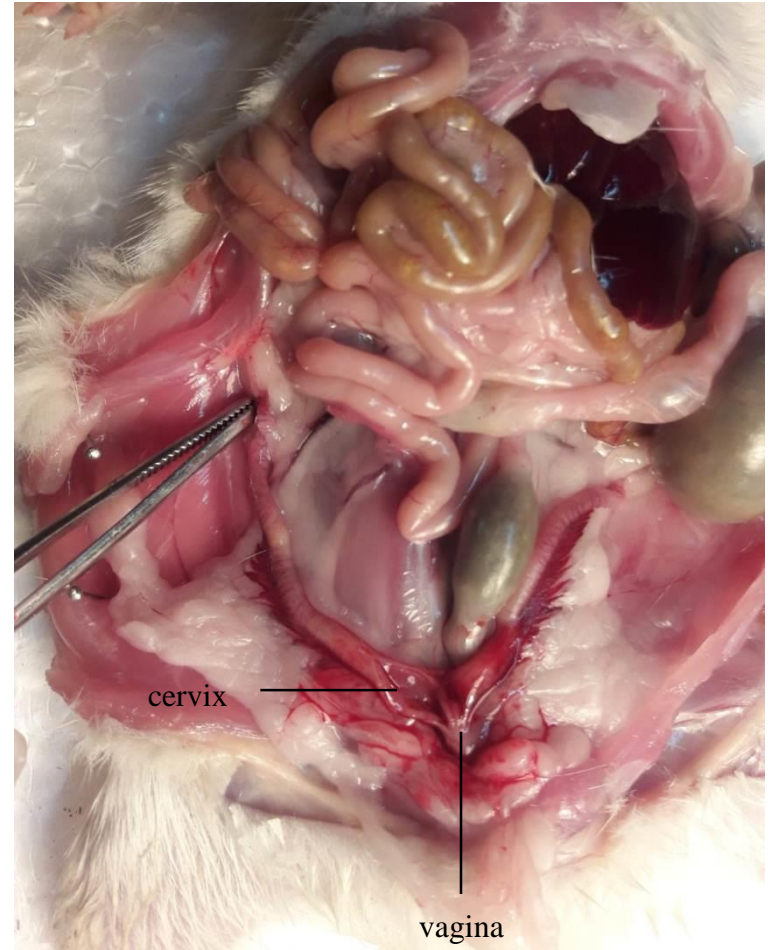
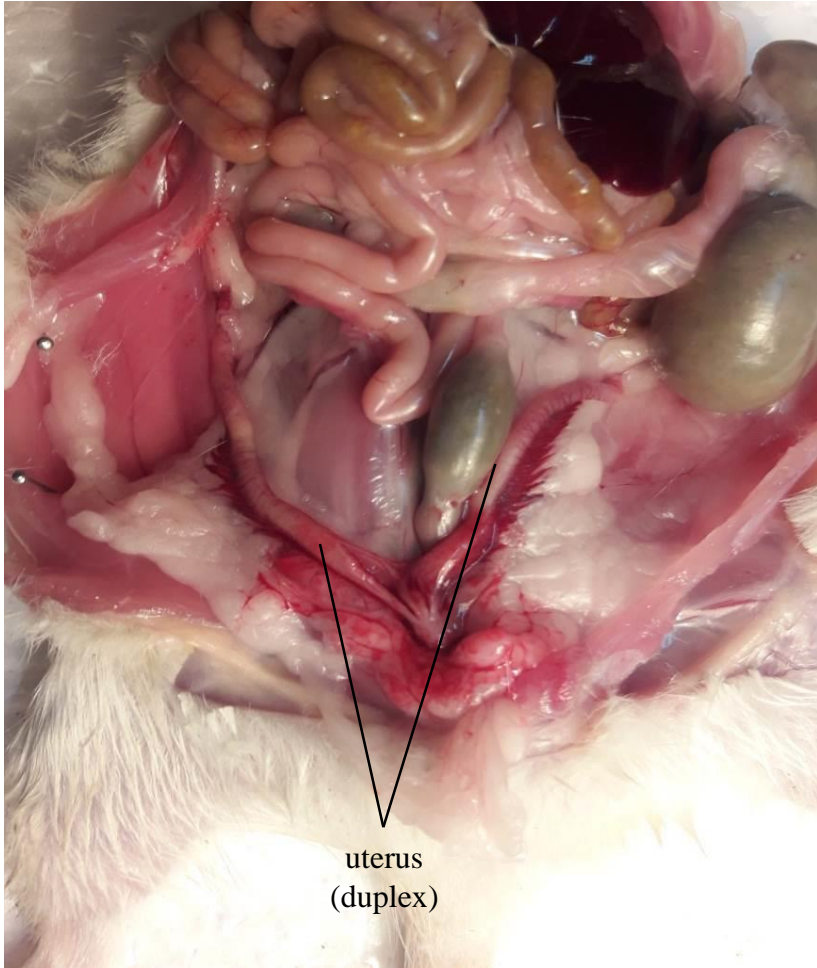


Genital system in female rat





Genital system in female rat





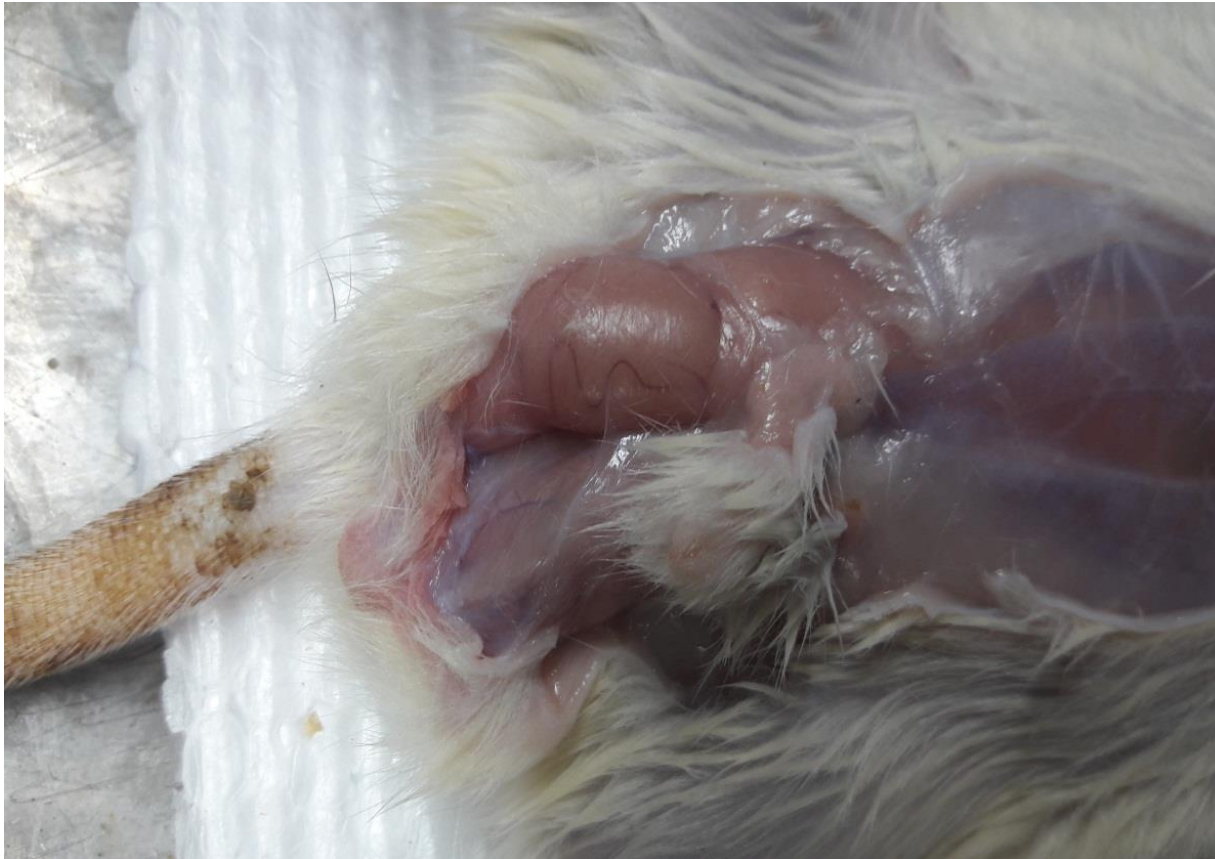
Genital system in male rat

- Genital system in male rats consist of
 - Paired testes
 - Ducts (epididymis, Vas deffereans, ejaculatory ducts, urethera)
 - Glands (seminal vesicle, coagulating glands, prostate, bulbourethral)

- Seminal vesicle secretes fructose, prostaglandins, ascorbic acid, proteolytic enzyme, zinc
- Prostate secretes proteolytic enzyme, zinc, antibacterial substance, glicoprotein



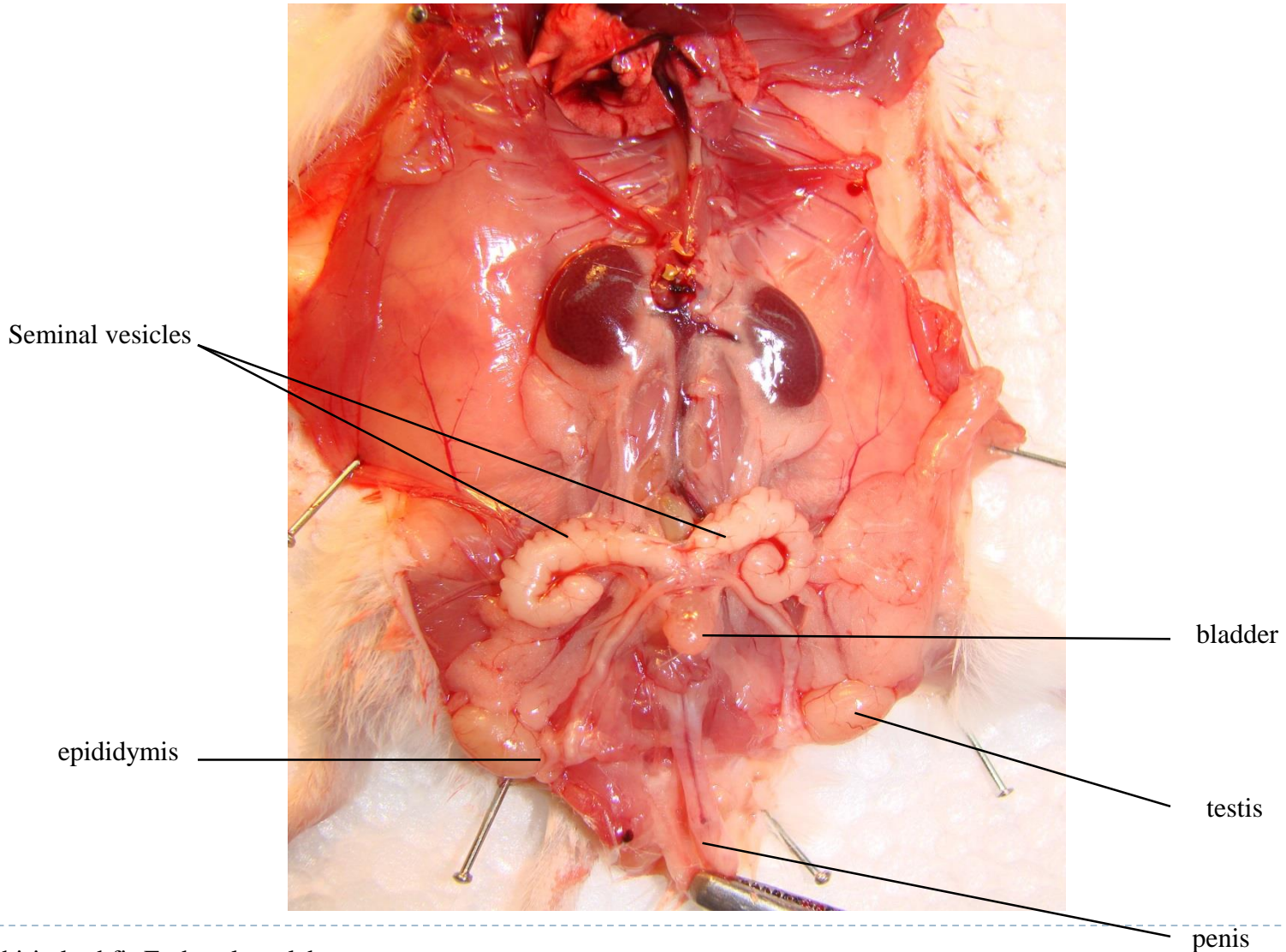
Genital system in male rat



Testes protect in scrotum

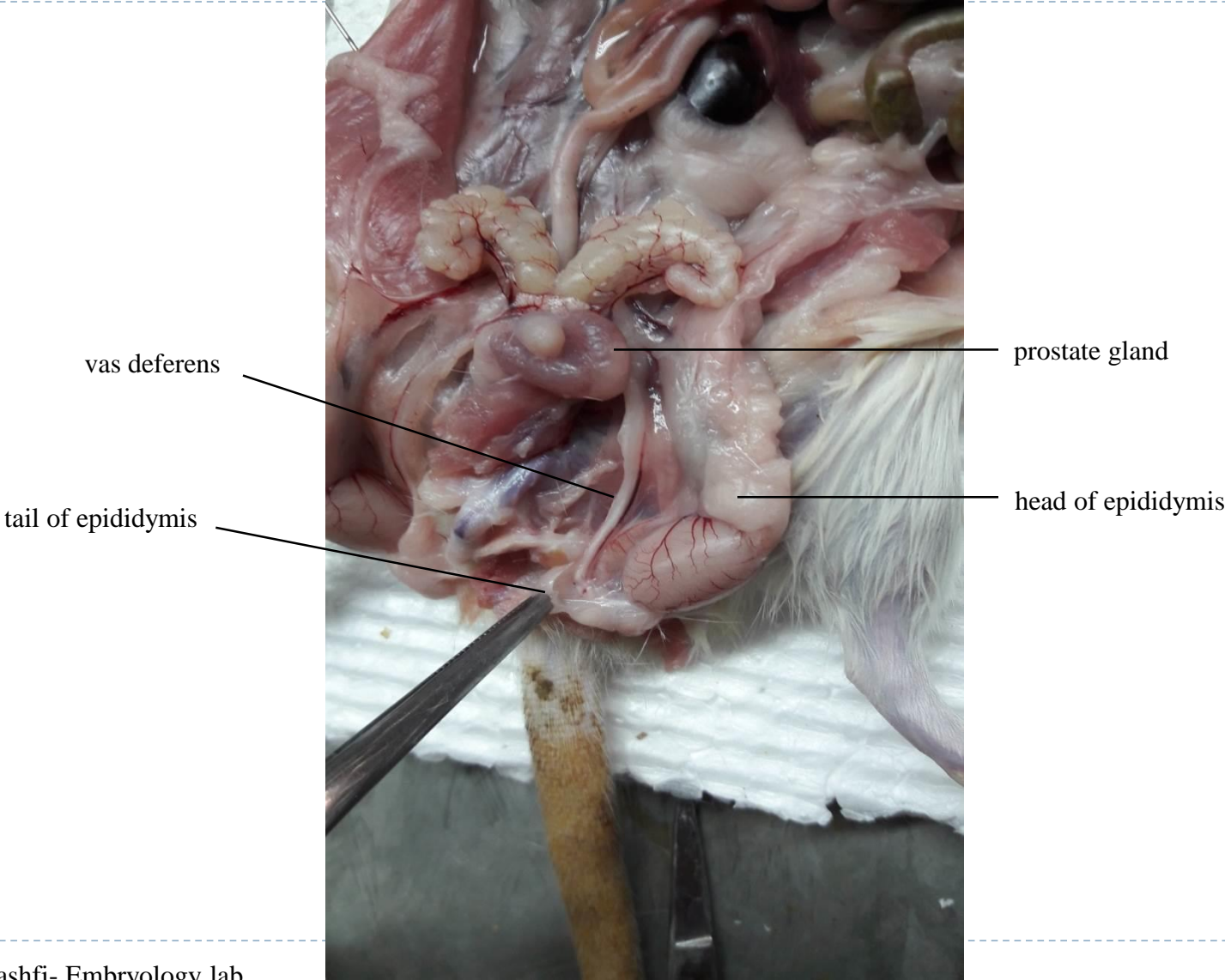


Genital system in male rat



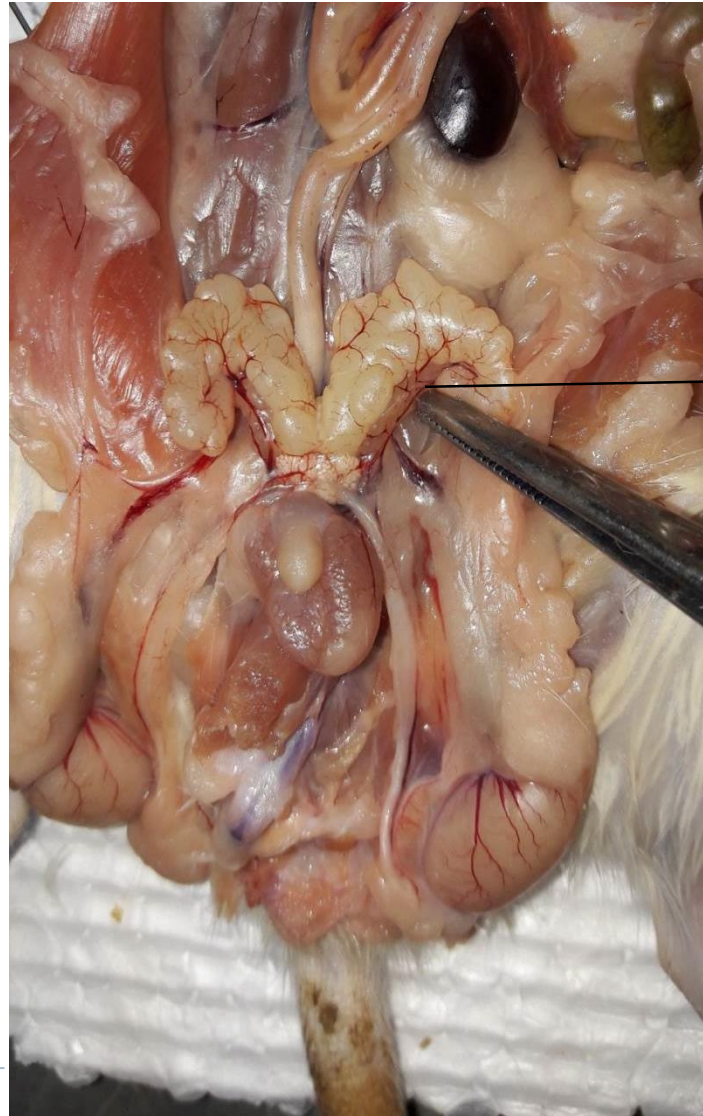


Genital system in male rat





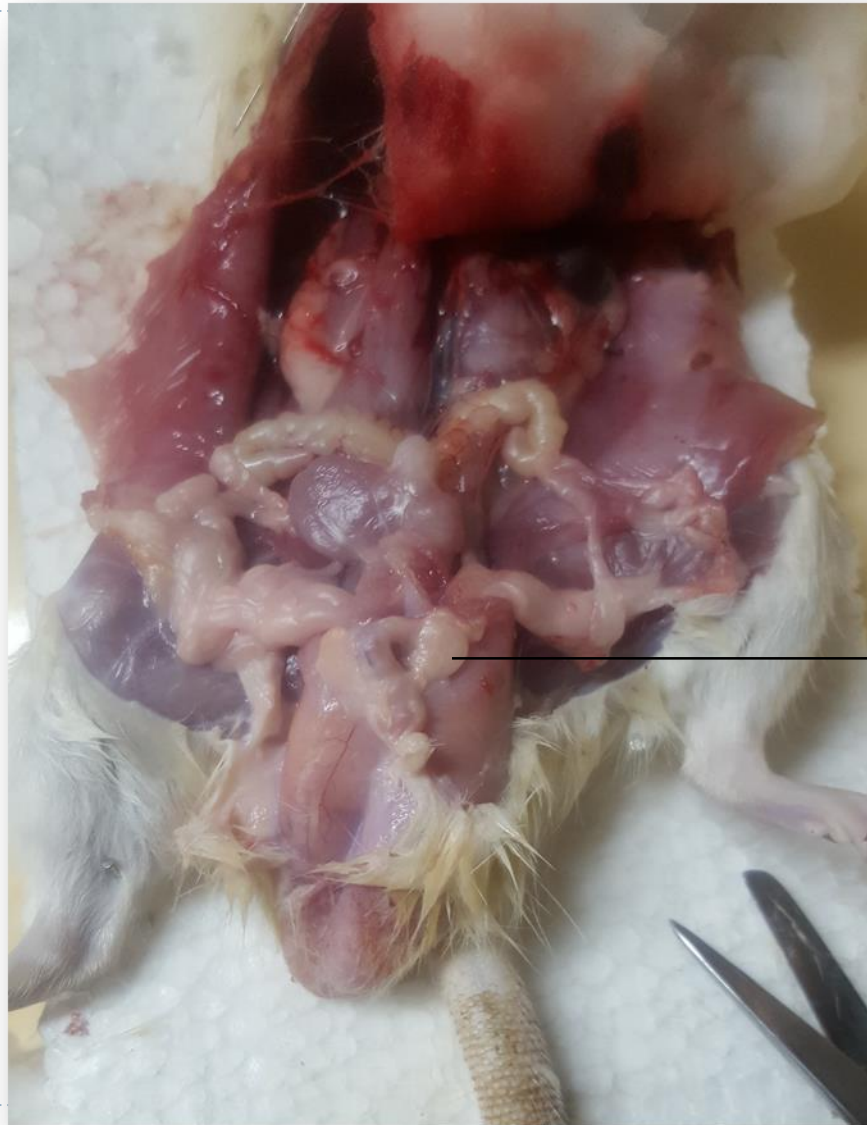
Genital system in male rat



coagulating gland



Genital system in male rat

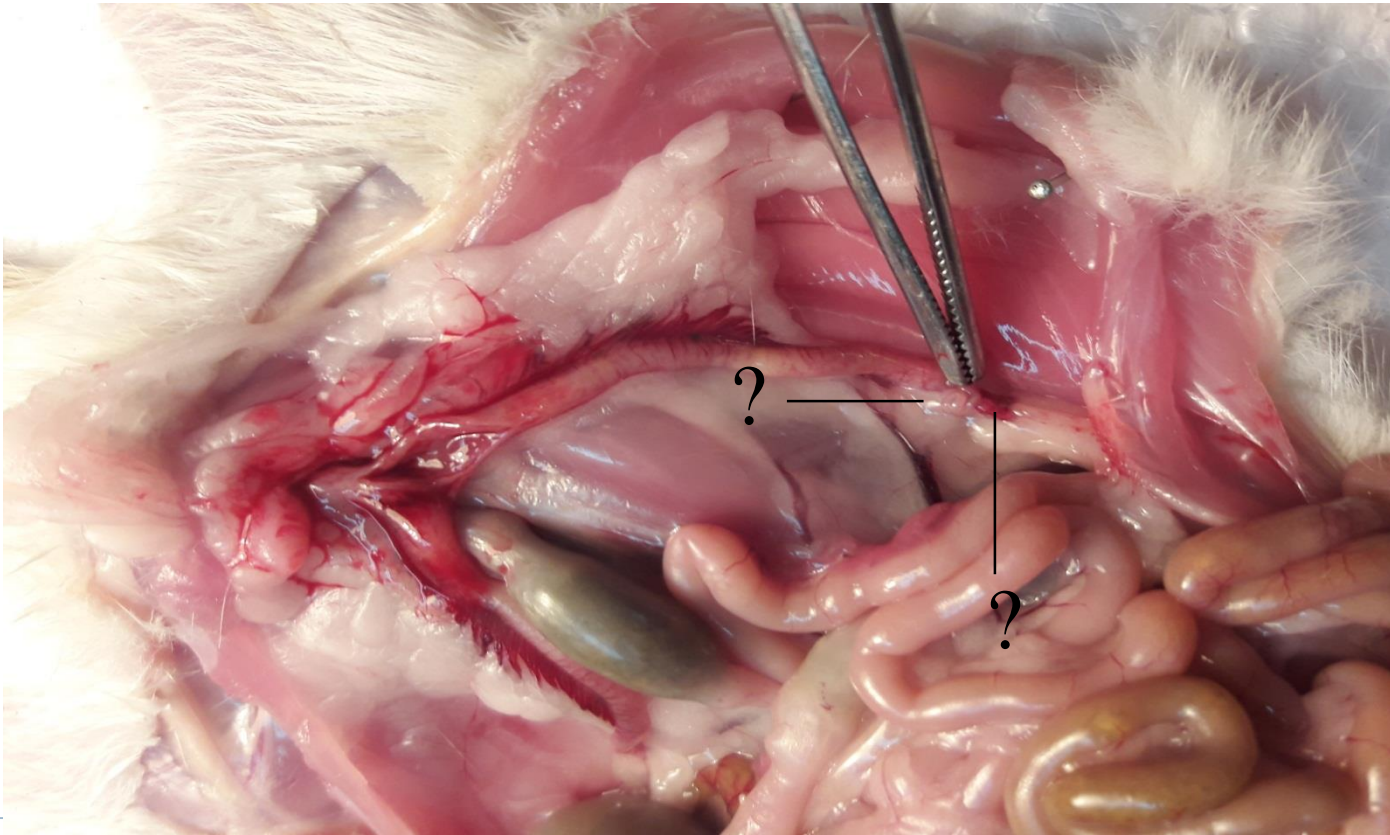


bulbourethral gland



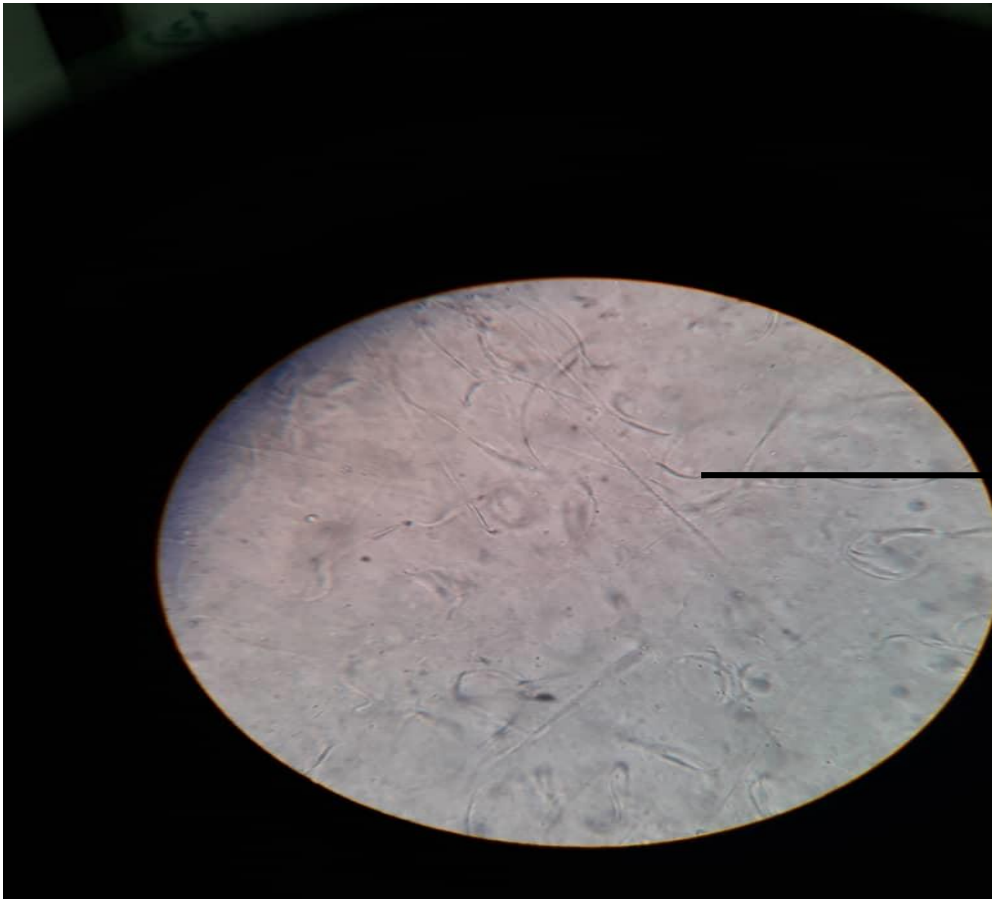
Quiz time!

- Name these parts





Rat sperms



اسپرم